Computed Tomography Scan (CT Scan)

- CT Scan makes use of computer-processed combinations of many X-ray measurements taken from different angles to produce cross-sectional (tomographic) images (virtual "slices") of specific areas of a scanned object, allowing the user to see inside the object without cutting.
- The term "computed tomography" (CT) is often used to refer to X-ray CT, because it is the most commonly known form.
- But, many other types of CT exist, such as positron emission tomography (PET) and single-photon emission computed tomography (SPECT).
- X-ray tomography, a predecessor of CT, is one form of radiography, along with many other forms of tomographic and non-tomographic radiography.

- In recent years, there has been a rapid increase in the availability of computed tomography (CT). Previously, these modalities were only available in universities or large referral institutions.
- Nowadays, first opinion practices are acquiring CT scanners and mobile imaging units make these advanced imaging modalities readily accessible to the veterinary profession.
- Since their development, CT has undergone continuous technological improvement and a large number of scientific papers describing features of diseases in animals have been published, contributing greatly to the advancements in clinical veterinary medicine.

- Computed tomography (CT) is a diagnostic imaging procedure that has become commonplace in first-opinion practices.
- This is continually undergoing technological improvement and each has its advantages for different applications.
- CT scanning will remain complex and expensive procedures. Fundamental differences exist between both technologies.
- Veterinarians are often faced with a choice between CT or MRI for the optimal diagnostic workup of their patients.
- A clear understanding of the strengths and weaknesses of both modalities will allow them to select the optimal imaging modality.

How does CT works?

- CT is a diagnostic imaging technique based on x-ray technology.
- The difference to conventional radiography is that x-rays are produced by a high-powered x-ray tube that rotates around a slice of the patient's anatomy.
- The x-ray beam is attenuated by the patient's anatomy to reach a panel of detectors, which transform the detected radiation into an electrical signal.
- The signal output is proportional to the density of the penetrated tissue. The computer generates a matrix image from the different projectional density values corresponding to the relative density of the different body parts.
- CT images are usually acquired in the transverse plane. Images in other planes (eg, sagittal, dorsal, oblique) can be reconstructed with specific software; however, the image resolution is inferior to the original transverse images, unless these were acquired with submillimeter slice width.

Conti…

- In honour of the inventor of CT, the attenuation values are specified in Hounsfield units (HU) or CT numbers.
- In theory, more than 4000 shades of grey could be represented on the monitor. However, the human eye is only able to differentiate 20 to 30 shades of grey.
- Therefore, it becomes necessary to adjust the image to an adequate range of CT numbers. This is known as windowing and levelling of the image.

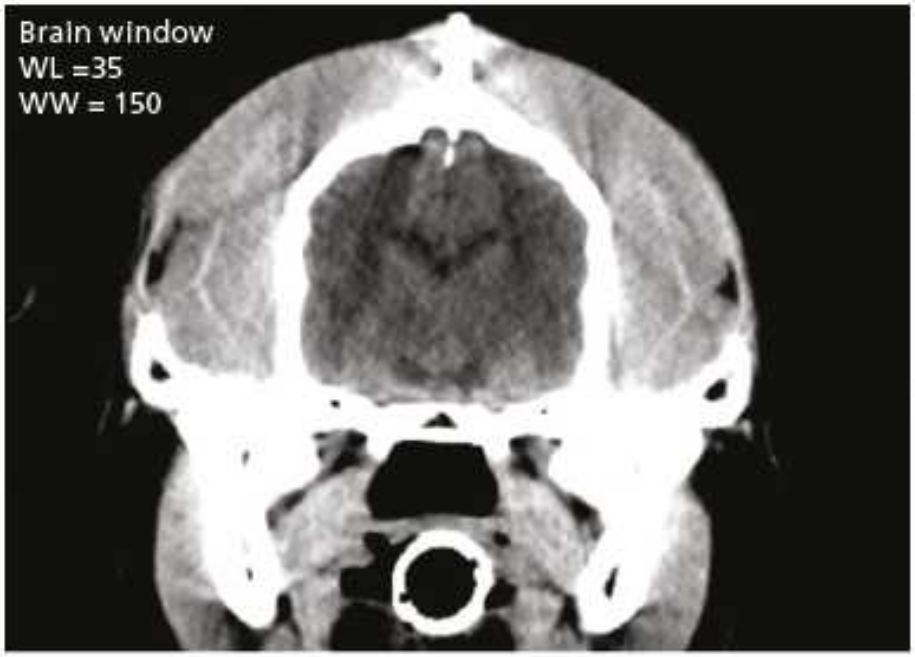

Here, WL- Window length
WW- Window width

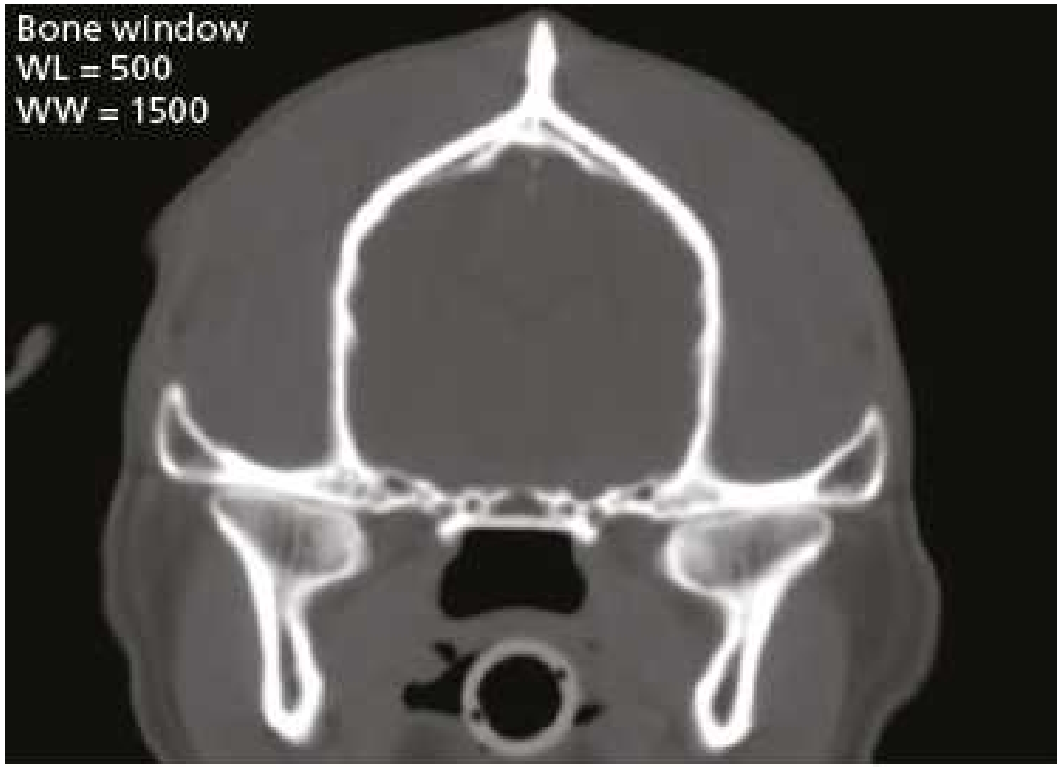

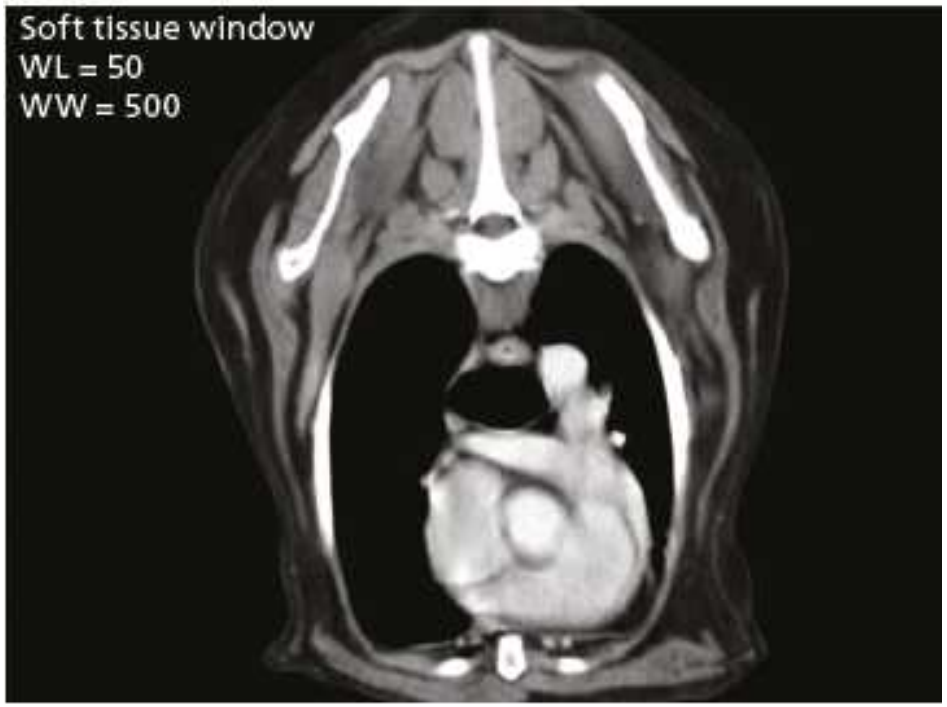
Soft tissue window
WL = 50
WW = 500


Lung window
WL =500
WW = 1500

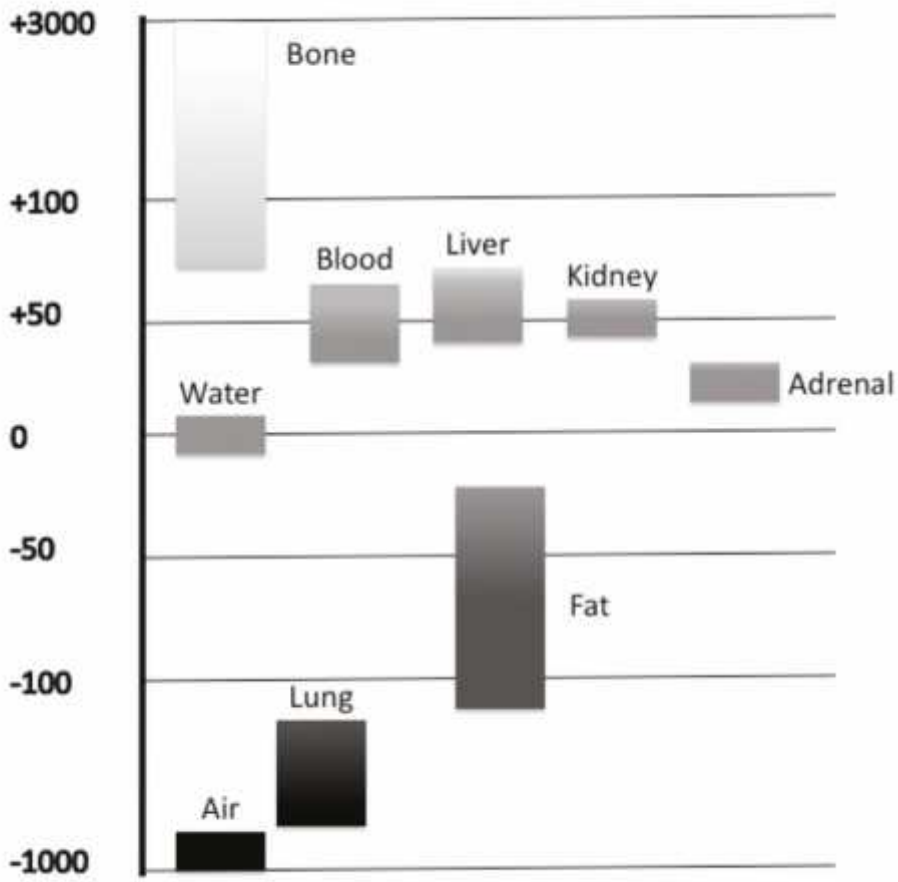

By convention, water has an HU = 0 and air has an HU = -1000. The HUs of other tissues are displayed as a value relative to the attenuation of water.

Types of CT Scanner

- **Single-slice CT scanners**: in this type of scanner, only one row of detectors is present. During each rotation of the tube, a single slice of anatomy is imaged.
- **Multi-slice CT scanners**: in these modern scanners, several rows of detectors are present, allowing acquisition of multiple slices of anatomy during each tube rotation. Dual-slice CT scanners were first introduced in the early 1990s. Since then, scanners with four, six, eight, 16, 64, 128 and more detector rows have become available and have made a marked impact on the role of CT in veterinary medicine.

The external appearance of a CT scanner

Indications for CT in small animals

- CT followed by arthroscopy is the current gold standard for imaging canine elbow dysplasia. Canine elbow dysplasia is a complex condition and encompasses osteochondrosis, medial coronoid disease and joint incongruity.

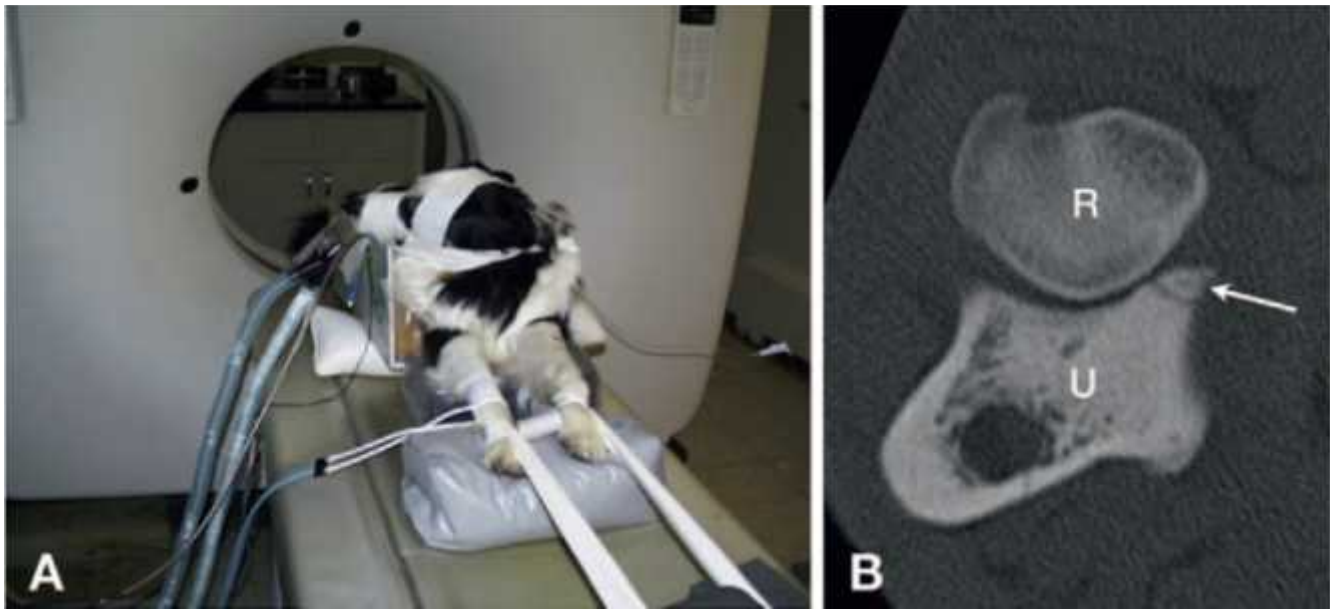

Elbow CT in a dog. (A) Positioning involves lateral flexion of the head away from the legs to avoid beam hardening and photon starvation artefacts (Picture courtesy of Tobias Schwarz). (B) There is fragmentation of the medial coronoid process (arrow) of the ulna (U), a very common pathologic entity in dogs, part of the canine elbow dysplasia complex.

- CT is also used in the evaluation of complex fractures, limb and vertebral deformities and various other joint diseases.
- Multiplanar reconstructions are essential, and 3D printing may become more frequently used in surgical planning.

3D volume rendered image of the skull of a normal cat. 3D reconstructions are increasingly used to teach normal anatomy to veterinary undergraduates.

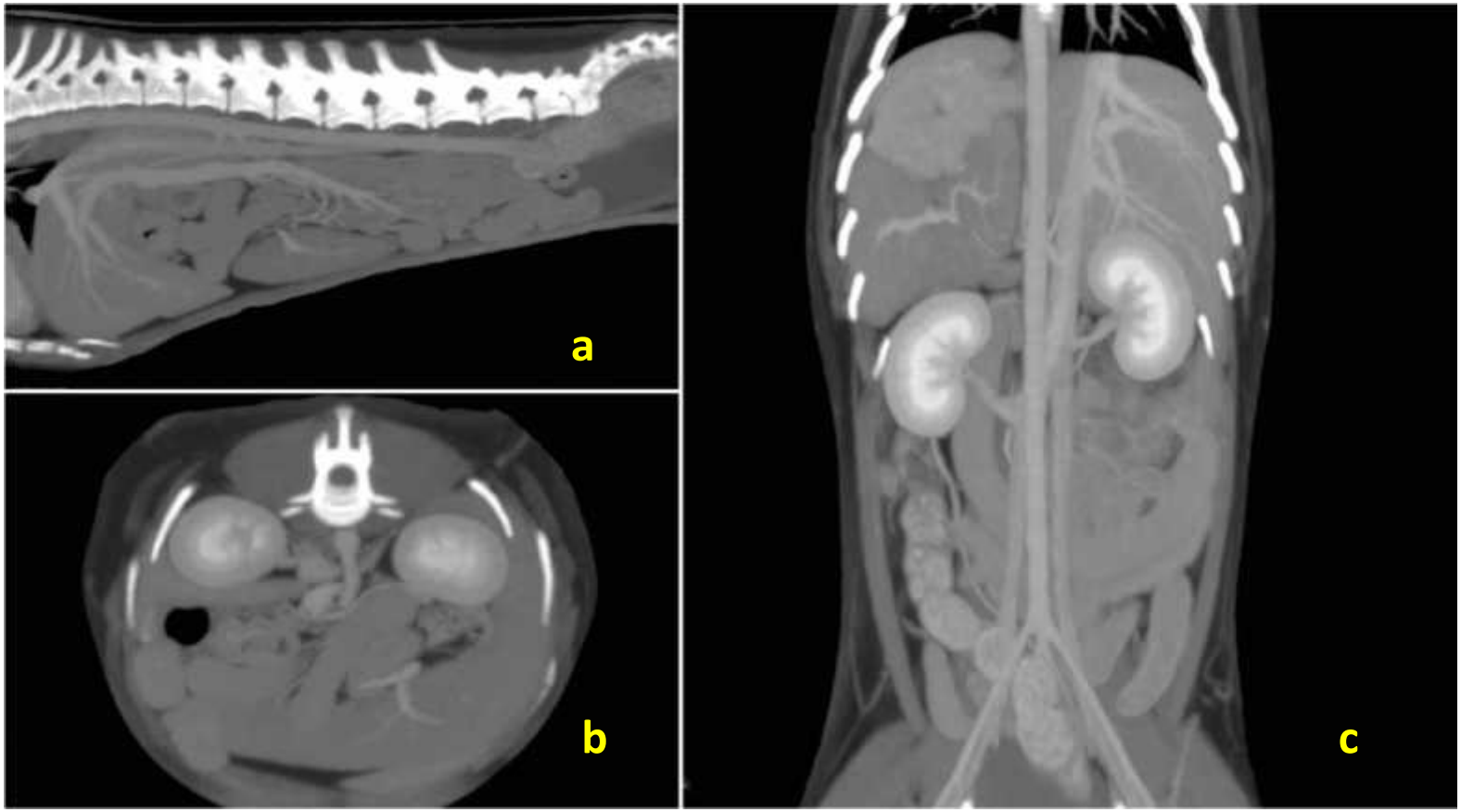

Multiplanar reconstruction (MPR) is the computer technique that allows. The images to be reformatted in any plane. (a) Sagittal, (b) transverse and (c) dorsal

- CT is used commonly for the assessment of sinonasal disease (nasal aspergillosis, nasal adenocarcinomas, rhinitis), ear disease (otitis media, nasopharyngeal polyps, aural neoplasia), facial swellings and masses, migrating foreign bodies (in particular oropharyngeal stick injuries) and oral masses.
- CT is well suited to identifying and following the ureters, particularly in cases of suspected ureteral ectopia. Ectopic ureter is the commonest cause of incontinence of juvenile female dogs; the Golden Retriever breed is predisposed.
- Ventral recumbency is preferred but with the hind legs raised on a foam block. This serves to prevent contrast pooling near the bladder neck, thus obscuring the ureteral entrances.
- Pre- and post-contrast scans are then performed to include the kidneys cranially to the tuber ischii caudally.
- The post-contrast scans are repeated until both ureteral entrances are seen.

- CT angiography is used relatively frequently at sites where rapid-injection pumps are installed.
- Some examples include the evaluation of portosystemic shunts, assessment of PTE cases, and dual-phase investigation of various types of neoplasia, such as insulinoma.
- Portosystemic shunts are relatively rare vascular anomalies found in dogs and cats and are defined as an anomalous connection between the systemic venous and portal venous system.

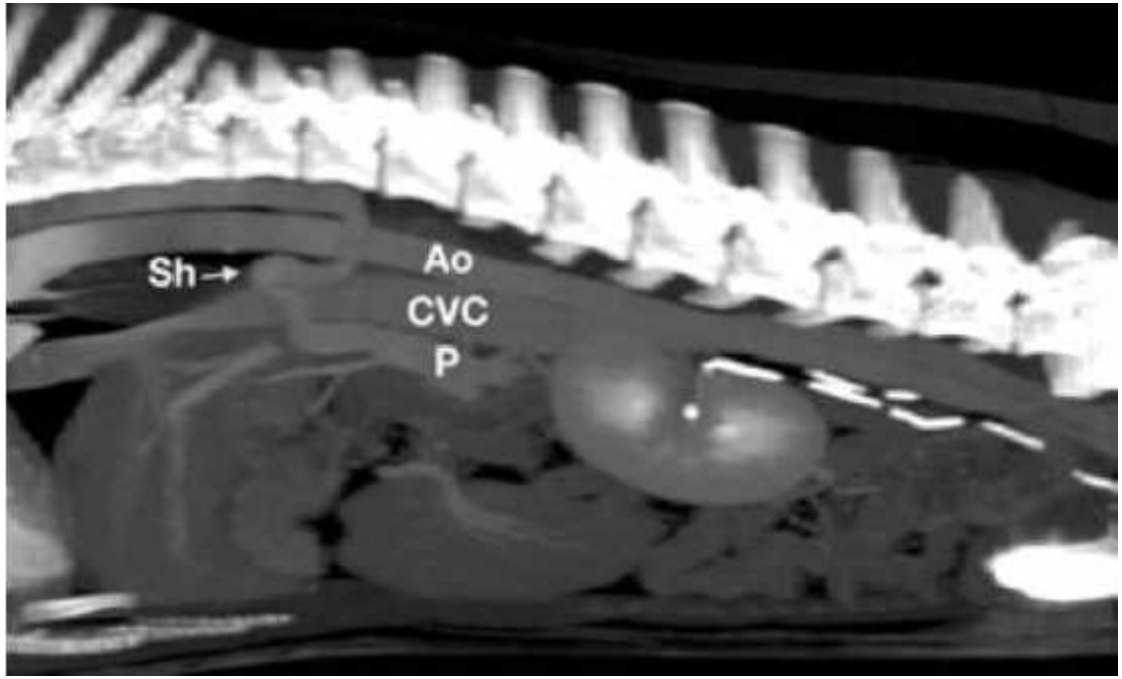

- CT angiography sagittal plane MIP, portal phase in a dog.
- There is a tortuous blood vessel extending from the portal vein (P) in a dorsal direction, joining the azygos vein ventral to the thoracic vertebrae.
- Diagnosis: porto-azygos shunt (sh).
- (Ao) Aorta, (CVC) caudal vena cava, (P) portal vein.

Indications for CT according to the anatomical region

	CT
Central nervous system	CT is modality of choice if MRI unavailable Helpful when lesion is vascularised Complementary to MRI in cases of trauma, fractures and bone malformations
Skull and splanchnocranium	Excellent and rapid Superior osseous details in general Evaluation of the teeth
Thorax	Imaging modality of choice Superior metastatic screening when compared to radiographs
Abdomen and pelvis	Excellent and rapid Superior osseous details
Musculoskeletal	Excellent and rapid Superior osseous details
Angiography	Excellent Best results obtained with helical scanners and rapid injection pump

Key differences between CT and MRI

CT	MRI
Ionising radiation	No ionising radiations
Based on x-ray technology	Relies on magnetic fields and radiofrequency pulses
X-ray beam attenuation as it passes through the body	Creates a map of hydrogen atoms in the body
Two main types of scanners: single-slice and multi-slice	Two main types of scanners: low- and high-field-strength
Image acquisition in transverse plane and reconstruction with near equivalent resolution in multi-slice scanners	Image acquisition in any plane
Thin slices (up to 0.5 mm)	Thicker slices (usually minimal 2 mm)
Quick acquisition, usually seconds to few minutes	Slow acquisition, usually about 30 to 60 minutes
Great imaging detail for bones	Great imaging detail for soft tissues
Equipment, setup and maintenance usually less expensive than MRI	Equipment, setup and maintenance usually more expansive than CT
Iodinated contrast media	Gadolinium-based paramagnetic contrast media